

Acute gouty arthritis attacks induced by a great toe injury: a case report and literature review

Jun Yang¹, Li Liu², Xiaopan Nie², Anni Jiang^{2,*}

¹*Department of Urology, Zigui County Hospital of Traditional Chinese Medicine, Yichang, 443600, Hubei, China*

²*Department of Clinical Psychology, People's Hospital of Wuhan University, Wuhan, 430061, Hubei, China*

**Corresponding author*

Keywords: Gouty arthritis, hyperuricemia, injury, drug treatment, benzbromarone

Abstract: Introduction: Gouty arthritis usually occurs in patients with hyperuricemia and can be induced by a variety of factors. Here, we describe a case of acute gouty arthritis attacks induced by a great toe injury and was successfully treated by benzbromarone and ibuprofen. Patient concerns: A 27-year-old Asian man with hyperuricemia informed us his first metatarsophalangeal joint of left foot began to redness and swelling, accompanied by severe pain presented 8 days after the toenail injury. Diagnoses: Laboratory tests confirmed as gouty arthritis with no signs of infection, but serum uric acid was significantly higher than normal at 523 $\mu\text{mol/L}$. Interventions: Drug treatment was adopted, including benzbromarone 100 mg daily, ibuprofen pills 75mg twice a day, and sodium bicarbonate tablets 0.5g three times a day. Outcomes: All of his symptoms of acute gouty arthritis attacks gradually disappear after drug treatment for a week and blood uric acid had dropped to 87 $\mu\text{mol/L}$ two weeks later. Conclusion: When patients with a broken great toe present with symptoms of first metatarsophalangeal joint began to redness and swelling, accompanied by severe pain, acute gouty arthritis attacks should also be considered, and the drug treatment is effective. Abbreviation: GA = Gouty arthritis, MSU = Monosodium urate, ESRD = End-stage renal disease.

1. Introduction

Gout, also called podagra, was defined as a feeling of pain in the first metatarsophalangeal joint[1]. It was closely related to a rich diet such as high-fat food and excessive drinking, which was only common in the wealthy social class in the past. Nowadays, gout is explicitly defined as a rheumatologic disease with a variety of clinical manifestations. In general, gouty arthritis (GA) has always been the most common clinical manifestation of gout and it usually presents an acute attack. Gout is the most common cause of inflammatory arthritis in American adults [2, 3]. Gout patients may develop tophi, uric acid nephrolithiasis, and interstitial nephropathy with the progress of the disease [4].

It has been shown that the incidence rate, prevalence rate, and health loss of gout are increasing in the recent decades according to the epidemiological evidence [5-8]. As the evidence showed, the

prevalence of males was higher than that of females [5], and there were 7.44 million cases of gout around the world in 2017 (incidence 0.097%), with a prevalence of 41.22 million cases (0.54%) [5]. The prevalent gout cases increased by 30% from 1990 to 2015 in Northern Europe, and the gout patients contributed to 7982 (95% UI 5431–10 800) years lived with disability in 2015, an increase of 29% from 1990 [9]. Therefore, the global burden of gout is enormous and may increase a lot in the future based on a large number of gout patients.

According to the available literature[10-19], gouty arthritis usually occurs in patients with hyperuricemia and it can be induced by a variety of factors. Here, we describe a case of acute gouty arthritis attacks caused by a great toe injury, which was successfully treated with benzbromarone and ibuprofen.

2. Case presentation

The case was provided by a 27-year-old male medical student who has provided informed consent for publication of the case. The medical student accidentally damaged the toenail on his left great toe in the summer of 2019 (**Figure 1, 0 h**). Since he lived in a remote mountainous area, far away from the hospital, most of the damaged toenail was removed by himself with only a small part of the root left (**Figure 1, 1 h**). After that, the wound was disinfected thoroughly with hydrogen peroxide, medical alcohol, and iodine, then wrapped with medical gauze. The wound was re-disinfected every 12 hours and then covered with gauze to prevent infection. The covering process was not sterile due to the lack of sterile medical devices. In the first two days after the injury, the student observed a small amount of exudate on the surface of the wound and the wound was indeed pain-sensitive (**Figure 1, Day 1-2**). On the third day after the injury, the wound surface began to dry and the pain was significantly reduced (**Figure 1, Day 3**). He could slowly put on his socks and shoes after the wound was covered with a new gauze, so he took a 12-hour train ride back to campus. On the fourth day, with the help of his classmates, he pulled out the remaining toenails without using any local anesthetics, feeling no pain (**Figure 1, Day 4**). He felt that the wound had begun to heal, so he took the bath normally, which means that he washed the wound with the bathwater. After the shower, the wound was disinfected thoroughly and then covered with new gauze and changed every 12 hours as before. The wound gradually dried out and healed from the fifth day until 37 days after the injury, over half of the new toenail grew back (**Figure 1, Day 5-37**), and was completely restored by the 50th day (**Figure 1, Day 50**).

However, there was something unexpected that happened in the meantime. On the eighth day after the injury, the first metatarsophalangeal joint of his left foot began to redness and swelling, accompanied with severe pain (**Figure 2, Day 8**), the student could not walk, bend or even touch the first metatarsophalangeal joint. He thought it might be a sudden contracted gouty arthritis as he realized that he was a patient with hyperuricemia (the blood uric acid value was between 480 and 530 $\mu\text{mol/L}$ for several years, **Figure 3, Time = 0 months**). With the help of his roommates, he carried out a series of laboratory tests at the hospital. He was diagnosed with gouty arthritis as there were no signs of infection in the results, but serum uric acid was significantly higher than normal at 523 $\mu\text{mol/L}$ (**Table 1, Figure 3, Time = Date of diagnosis**). He began to take drugs orally, including benzbromarone 100 mg daily, ibuprofen pills 75mg twice a day, and sodium bicarbonate tablets 0.5g three times a day. Nine days after the injury (the day after the gout attack), the swelling in the first metatarsophalangeal joint of his left foot was much more serious than ever before. The back of his foot was swollen (**Figure 2, Day 9**), and the shoes could no longer support his left foot. Also, the joint pain significantly increased, seriously affecting his sleep, not to mention walking. However, from the 10th day after the injury, the pain and swelling of his first metatarsophalangeal joint began to reduce, and the swelling of his foot gradually improved (**Figure 2, Day 10 and 12**). By the 14th

day after the injury (a week after the gout attack), the swelling of his left first metatarsophalangeal joint and back of foot had subsided and the pain had been significantly relieved (**Figure 2, Day 14**). He stopped ibuprofen but continued to take benzbromarone and sodium bicarbonate tablets for a week, then he underwent a laboratory test with uric acid levels at $87 \mu\text{mol/L}$ (**Figure 3, Time = 3.5 months**). Considering that the gouty arthritis was cured, he stopped taking benzbromarone and sodium bicarbonate tablets and changed to a conservative treatment to control blood uric acid levels through dietary adjustments. Two weeks later, he re-examined with the uric acid levels at $380 \mu\text{mol/L}$ (**Figure 3, Time = 4 months**). After that, he subsequently re-examined the blood uric acid on 3, 6, and 9 months after the gout attack, the level has fluctuated between 460 and $508 \mu\text{mol/L}$ (**Figure 3, Time = 6-12 months**). Now, the student plans to follow a strict diet under the guidance of his teacher to prevent a recurrence of gout.

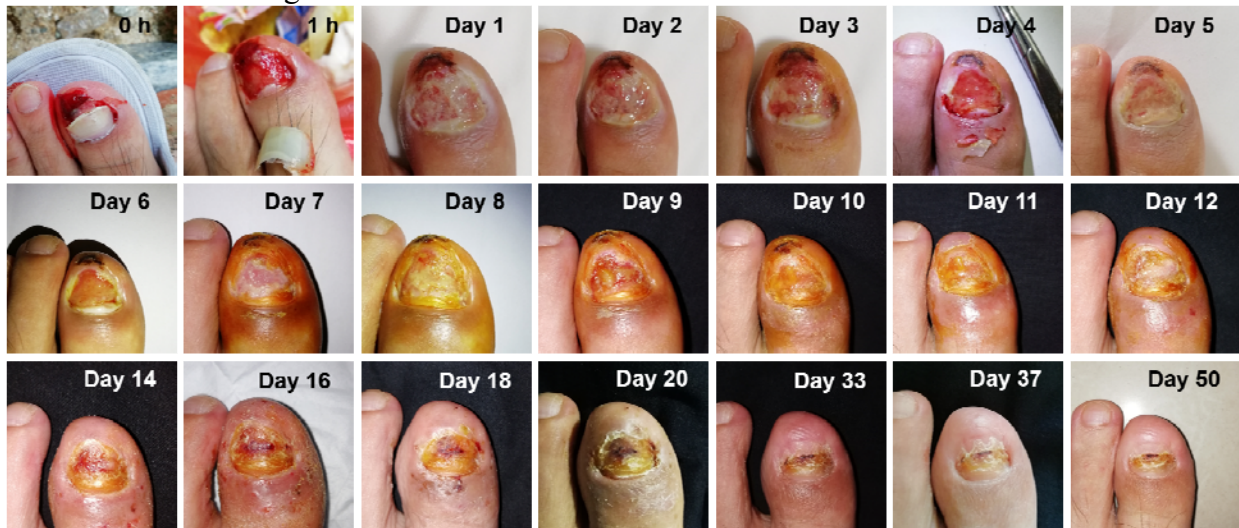

Figure 1: The healing process after toenail injury. 0h: Initial post-traumatic appearance; 1h: The appearance of the damaged nail after removal; Day 1: The first day after the trauma, Day 2 to Day 50 and so on.

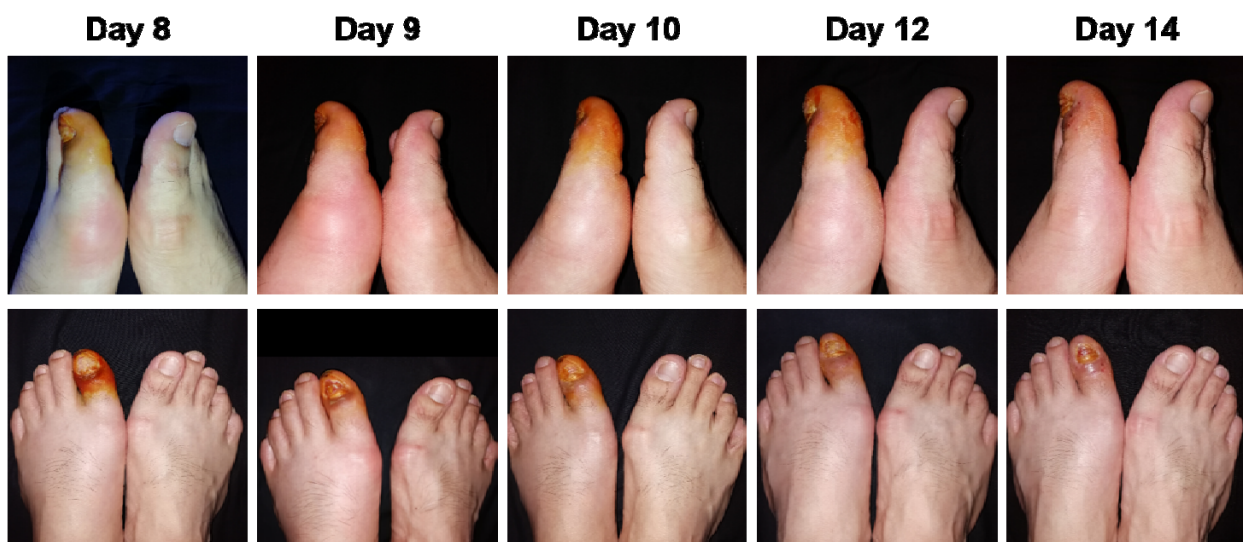

Figure 2: The appearance of first metatarsophalangeal joint and back of foot during gouty arthritis attacks. Day 8: The first day of gouty arthritis attacks, and the eighth day after the trauma, Day 9 to Day 14 and so on.

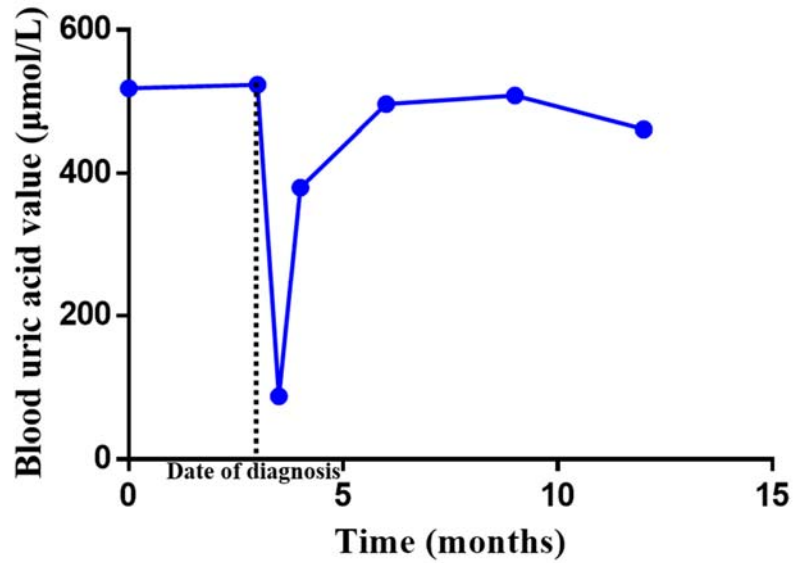


Figure 3: The blood uric acid value fluctuation curve. The lowest value was measured 2 weeks after taking the drugs.

Table 1: Laboratory test results at the time of diagnosis

Test	Value	unit	Value range
White blood cell count	7.33	$10^9/L$	4~10
Red blood cell count	4.56	$10^{12}/L$	4~5.5
Hemoglobin	142	g/L	120~160
Platelet count	205	$10^9/L$	100~300
Lymphocyte percentage	32.10	%	20~40
Neutrophilic granulocyte percentage	57.20	%	50~70
Eosinophils percentage	1.50	%	0.5~5
Basophil percentage	0.10	%	0~1
Lymphocyte count	2.35	$10^9/L$	0.8~4
Neutrophil count	4.19	$10^9/L$	1.8~6.3
Eosinophil count	0.11	$10^9/L$	0.05~0.5
Basophil count	0.01	$10^9/L$	0~0.1
Erythrocyte sedimentation rate	9	mm/h	Male: 0~15
C reactive protein	4	mg/L	<5
Uric acid	523	µmol/L	149~450
Serum creatinine	62	µmol/L	53~106
Blood urea nitrogen	5.6	mmol/L	2.9~7.5

3. Discussion

As a clinical syndrome, gout is characterized by increasing deposition of urate and monosodium urate (MSU) crystal in tissues, leading to arthritis, tophi, nephrolithiasis, and urate nephropathy[20-22]. The clinical characteristics of gout are due to the inflammatory response to MSU crystals[23]. The renal and gut excretion of urate is the main factor in regulating serum urate[24], and the root cause of gout is that the uric acid level increased chronically and exceeded the saturation point for MSU crystal formation. The first manifestation is mainly a peripheral joint synovitis attack with severe pain, which is always called acute self-limiting attacks. With the development of gout, joint injury and deformity, chronic usage-related pain, and subcutaneous tophus deposition can be eventually developed [25]. Although the exact pathogenesis of gout is still unclear, more and more evidence suggests that genetic factors, environmental factors, and immune imbalance may be involved in the development of gout [26]. A recent review[25] also shows that some ethnic groups are particularly susceptible to gout, supporting the importance of genetic predisposition. Socioeconomic and dietary factors, as well as comorbidities and drugs that may influence uric acid levels and/or promote MSU crystal formation, are also important in determining the risk of developing clinically significant gout[25]. As gout occurs due to the inflammatory response to MSU crystals, the effective treatment strategy is crystal dissolution [23]. In clinical practice, non-steroidal anti-inflammatory drugs, colchicine, or corticosteroids are often used to treat GA [3, 27, 28].

The prevalence of gout has continued to rise for decades, especially in the United States. The number of outpatients hospitalized for gout increased three times from 1993 to 2009, with the most significant increase after 2003[29]. Another study[30] showed that the number of gout admissions in Australia and New Zealand increased significantly during 2009-2014, gout has become an increasingly serious problem affecting Australian individuals and the community as a whole. The incidence rate of acute GA in the Chinese mainland was also increased from 2000 to 2014 due to changes in diet and population structure[31]. The social burden of gout is enormous worldwide.

Although GA is a self-limited noninfectious inflammatory disease, long-term prophylactic gout therapy should be considered to prevent or reduce the risk of recurrent acute GA. The prophylactic gout treatment mainly includes nonpharmacologic and pharmacologic strategies, the former is recommended for all patients with a history of gout. Herein, an early diagnosis of GA has important clinical significance for early prevention of gout.

Many factors are leading to GA in patients with hyperuricemia. Bottiglieri et al.[11] described a case of GA attacks induced by gemcitabine chemotherapy in a 66-year-old Caucasian male after pancreatic surgery. With the prophylactic medications consisting of allopurinol 100 mg and colchicine 0.6 mg daily during the whole period of gemcitabine chemotherapy could prevent GA attack. Mohamed et al.[10] reported a case of acute gouty monoarthritis of the left ankle in a 58-year-old female with chronic renal insufficiency. After the cryoablation of a 3.8 cm left renal cell carcinoma, the patient's symptoms disappeared after intravenous Solumedrol. Einarson et al.[12] presented a case of a patient with a history of GA attacks who suffered similar attacks after receiving cimetidine and ranitidine. He felt no attacks again during the therapy with H2-receptor antagonists. Van et al.[13] reported a case of a gout patient who experienced an attack in the third month of pregnancy, and her attack was well controlled by hydrocodone and allopurinol. It was hypothesized that her pregnancy resulted in insulin resistance, reducing the renal excretion of urate, and eventually provoked the flare. Alici et al.[14] presented a case of a 58-year-old hypertensive man with several episodes of pain and swelling in the first interphalangeal joint of the right great toe. The appearance and recurrence of symptoms occurred after sildenafil was used, and there were no symptoms after withdrawal of the drug. The gout was diagnosed based on the synovial fluid analysis. Dhaese et al.[15] reported a case of a 51-year-old white male normouricemic renal transplant recipient, who suffered from consecutive

attacks of severe neck, wrist, and ankle pain, accompanied by a persistent fever, did not respond to empiric antibiotic treatment. The MSU crystal was found through the analysis of aspirated ankle joint fluid, and colchicine treatment significantly improved the clinical condition of the patient. Choi et al.[16] described a case of acute GA after percutaneous radiofrequency thermal ablation for a hepatocellular carcinoma lesion in a 71-year-old male patient with underlying chronic renal insufficiency. Ji et al.[29] reported a case of a 52-year-old male patient with secondary gout due to primary myelofibrosis. After the treatment of primary myelofibrosis, the gout symptom was partially alleviated. Pela et al.[18] reported their observation of 5 patients (3 males and 2 females) aged 13-18 years and developed gout 2-84 months after renal transplantation. Calderon et al.[19] reported a case of a 69-year-old male patient with asymptomatic hyperuricemia who developed gout for the first time after a carpal tunnel release. Besides, a study[32] found that the frequency of GA in Japanese patients with end-stage renal disease (ESRD) was similar to that in the general population with hyperuricemia. It was slightly lower before dialysis and significantly lower after dialysis. Another study[33] reported a significant improvement in GA in dialyzed ESRD patients, with 70% of the patients had no recurrence of painful attacks, and the attack frequency decreased 50% in 30% patients. Although all patients had persistent hyperuricemia and more than 45% dialyzed ESRD patients had elevated uric acid levels, new-onset GA was extremely rare, even after 20 years of hyperuricemia.

This article reported a rare trigger of GA, hyperuricemia combined with a great toe trauma, which was worthy of clinical attention. When the first metatarsophalangeal joint swelling and severe pain occurred in patients with a broken great toe, acute GA attacks should also be considered, and the drug treatment was effective. To avoid an acute attack of GA, hyperuricemia patients should control the level of uric acid and diet strictly in their daily life.

Acknowledgments

We sincerely thank the medical students who provided us with medical records and authorized us to publish this article.

Funding: This research received no specific grant from any funding agency in the public, commercial, or not-for-profit sectors.

Data Availability Statement: The datasets used and/or analyzed during the current study are available from the corresponding author on reasonable request.

Conflict of Interest

The authors declare that there is no conflict of interest.

References

- [1] Nuki G, Simkin PA. A concise history of gout and hyperuricemia and their treatment. *Arthritis Res Ther* 2006;8 Suppl 1(Suppl 1):S1.
- [2] Khanna D, Fitzgerald JD, Khanna PP, Bae S, Singh MK, Neogi T et al. 2012 American College of Rheumatology guidelines for management of gout. Part 1: systematic nonpharmacologic and pharmacologic therapeutic approaches to hyperuricemia. *Arthritis care & research*. 2012 Oct;64(10):1431-46.
- [3] Khanna D, Khanna PP, Fitzgerald JD, Singh MK, Bae S, Neogi T et al. 2012. American College of Rheumatology guidelines for management of gout. Part 2: therapy and antiinflammatory prophylaxis of acute gouty arthritis. *Arthritis care & research* 2012 Oct;64(10):1447-61.
- [4] Wilson L, Saseen JJ. Gouty Arthritis: A Review of Acute Management and Prevention. *Pharmacotherapy*. 2016 Aug;36(8):906-22.
- [5] Mattiuzzi C, Lippi G. Recent updates on worldwide gout epidemiology. *Clin Rheumatol*. 2020 Apr;39(4):1061-63.
- [6] Roddy E, Choi HK. Epidemiology of gout. *Rheum Dis Clin North Am*. 2014. May;40(2):155-75.
- [7] Roddy E, Doherty M. Epidemiology of gout. *Arthritis Res Ther*. 2010;12(6):223.

- [8] Weaver AL. *Epidemiology of gout. Cleve Clin J Med.* 2008. Jul;75 Suppl 5:S9-12.
- [9] Kiadaliri AA, Uhlig T, Englund M. *Burden of gout in the Nordic region, 1990-2015: findings from the Global Burden of Disease Study 2015. Scand J Rheumatol.* 2018. Sep;47(5):410-17.
- [10] Mohamed AZ, Wallach WJ, Lu S, Zwiebel B, Hoots G. *Acute gouty arthritis following percutaneous cryoablation of renal cell carcinoma. Radiology case reports.* 2019. Nov;14(11):1432-37.
- [11] Bottiglieri S, Tierson N, Patel R, Mo JH, Mehdi S. *Gemcitabine-induced gouty arthritis attacks. J Oncol Pharm Pract.* 2013 Sep;19(3):284-8.
- [12] Einarson TR, Turchet EN, Goldstein JE, MacNay KR. *Gout-like arthritis following cimetidine and ranitidine. Drug intelligence & clinical pharmacy.* 1985. Mar;19(3):201-2.
- [13] Van Veen TR, Haeri S. *Gout in pregnancy: a case report and review of the literature. Gynecologic and obstetric investigation.* 2015;79(4):217-21.
- [14] Alici T, Imren Y, Erdil M, Gundes H. *Gouty arthritis at interphalangeal joint of foot after sildenafil use: A case report. International journal of surgery case reports.* 2013;4(1):11-4.
- [15] Dhaese S, Stryckers M, Van Der Meersch H, Terryn W, Van Laecke S. *Gouty arthritis of the spine in a renal transplant patient: a clinical case report: an unusual presentation of a common disorder. Medicine.* 2015 Apr;94(13):e676.
- [16] Choi DH, Lee HS. *A case of gouty arthritis following percutaneous radiofrequency ablation for hepatocellular carcinoma. World journal of gastroenterology.* 2010. Feb 14;16(6):778-81.
- [17] Ji LL, Hao YJ, Zhang ZL. *[A case of gout secondary to primary myelofibrosis]. Beijing da xue xue bao Yi xue ban = Journal of Peking University Health sciences.* 2018. Dec 18;50(6):1117-19.
- [18] Pela I, Seracini D, Lavoratti G, Materassi M. *[Acute gouty arthritis in adolescents with renal transplants]. La Pediatria medica e chirurgica : Medical and surgical pediatrics.* 1999. May-Jun;21(3):135-7.
- [19] Calderon MS, Chung KC. *Case report. Initial manifestation of gout after carpal tunnel release. British journal of plastic surgery.* 1999. Jan;52(1):76-7.
- [20] Richette P, Bardin T. *Gout. Lancet.* 2010. Jan 23;375(9711):318-28.
- [21] Baker JF, Schumacher HR. *Update on gout and hyperuricemia. Int J Clin Pract.* 2010. Feb;64(3):371-7.
- [22] Cleophas MCP, Crişan TO, Klück V, Hoogerbrugge N, Netea-Maier RT, Dinarello CA et al. *Romidepsin suppresses monosodium urate crystal-induced cytokine production through upregulation of suppressor of cytokine signaling 1 expression. Arthritis Res Ther.* 2019. Feb 6;21(1):50.
- [23] McCarty DJ, Hollander JL. *Identification of urate crystals in gouty synovial fluid. Ann Intern Med.* 1961. Mar;54:452-60.
- [24] Dalbeth N, Merriman TR, Stamp LK. *Gout. Lancet.* 2016. Oct 22;388(10055):2039-52.
- [25] Kuo CF, Grainge MJ, Zhang W, Doherty M. *Global epidemiology of gout: prevalence, incidence and risk factors. Nat Rev Rheumatol.* 2015. Nov;11(11):649-62.
- [26] Taniguchi A, Kamatani N. *Control of renal uric acid excretion and gout. Curr Opin Rheumatol.* 2008. Mar;20(2):192-7.
- [27] Jordan KM, Cameron JS, Snaith M, Zhang W, Doherty M, Seckl J et al. *British Society for Rheumatology and British Health Professionals in Rheumatology guideline for the management of gout. Rheumatology (Oxford).* 2007. Aug;46(8):1372-4.
- [28] Zhang. *EULAR evidence based recommendations for gout. Part II: Management. Report of a task force of the EULAR Standing Committee For International Clinical Studies Including Therapeutics (ESCSIT). Annals of the Rheumatic Diseases.* 2006;65(10):1312-24.
- [29] Krishnan E, Chen L. *Trends in physician diagnosed gout and gout therapies in the US: results from the national ambulatory health care surveys 1993 to 2009. Arthritis Res Ther.* 2013 Nov 6;15(6):R181.
- [30] Robinson PC, Kempe S, Tebbutt I, Roberts L. *Epidemiology of inpatient gout in Australia and New Zealand: temporal trends, comorbidities and gout flare site. Int J Rheum Dis.* 2017 Jun;20(6):779-84.
- [31] Liu R, Han C, Wu D, Xia X, Gu J, Guan H et al. *Prevalence of Hyperuricemia and Gout in Mainland China from 2000 to 2014: A Systematic Review and Meta-Analysis. BioMed research international.* 2015;2015:762820.
- [32] Ohno I, Ichida K, Okabe H, Hikita M, Uetake D, Kimura H et al. *Frequency of gouty arthritis in patients with end-stage renal disease in Japan. Internal medicine (Tokyo, Japan).* 2005. Jul;44(7):706-9.
- [33] Ifudu O, Tan CC, Dulin AL, Delano BG, Friedman EA. *Gouty arthritis in end-stage renal disease: clinical course and rarity of new cases. American journal of kidney diseases : the official journal of the National Kidney Foundation.* 1994. Mar;23(3):347-51.