

A bilateral Achilles masses male patient with mental retardation in Macao ----- A case report of rare Cerebrotendinous xanthomatosis and literature review

Ieong Chon Man, Kong Soi Chau*

Department of Radiology, Centro Hospitalar Conde de S. Januário, 999078, Macao SAR, China.

**Correspondence: stevensckong@gmail.com*

Keywords: Bilateral Xanthoma; Tendoachilles; Dyslipidmia; Cerebrotendinous xanthomatosis;

Abstract: Introduction: Cerebrotendinous xanthomatosis is a rare disease that is related to autosomal recessive inheritance of cholesterol metabolism. Early diagnosis is essential to the treatment and change the course of the disease. **Case Report:** This study reports a case of a 57-year-old man with painful Achilles tendon mass and no typical gout who was diagnosed in our hospital. He had history of mental retardation since childhood. He also presented with chronic diarrhea for many years. He was performed the laboratory examination revealed dyslipidemia. MRI of lower extremities showed two lobulated masses in the bilateral Achilles tendon regions, isointensity on T1WI, iso-hyperintensity on T2WI and heterogeneous enhancement, suggesting that the disease was xanthoma. Then biopsy of the tumors were performed and pathology confirmed the diagnosis of xanthoma. Brain CT showed cerebral atrophy and bilateral focal cerebellar lesions. Clinical symptoms, hyperlipidemia and imaging examination of this patient suggested diagnosis of cerebrotendinous xanthomatosis and the genetic mutation test (CYP27A1) confirmed the diagnosis of cerebrotendinous xanthomatosis. **Conclusion:** Cerebrotendinous xanthomatosis is a rare disease. The radiologist should pay attention to this disease and recommended neuroimaging to obtain a final diagnosis. Genetic test was suggested to confirm the diagnosis.

1. Introduction

Cerebrotendinous xanthomatosis (CTX) is a rare autosomal recessive inheritance of cholesterol metabolism [1]. Cerebrotendinous xanthomatosis is a congenital disorder of lipid metabolism, which is caused by CYP27A1 (CYP450, subfamily XXVIIA) at 2q35. The deficiency of polypeptide 1 gene leads to the failure of sterol 27 hydroxylase in the mitochondria, resulting in the failure of cholesterol and cholesterol metabolism in lipids, and accumulation in multi organ tissues, resulting in various pathological changes. Xanthoma is one specific manifestation of cerebrotendinous xanthomatosis. Xanthoma is a kind of proliferate lesion due to accumulation of fat. The pathological characteristics are the accumulation of lipid-rich macrophages, giant cells, and other inflammatory cells that respond to the deposition of cholesterol in tissues. Xanthoma is more

common on the skin, including the eyelids [18]. However, occurrence in the Achilles tendon is relatively rare and there have been few reports [2-3]. Most patients develop this disease in their thirties and the incidence is higher in females than males. CTX is a rare disease that is characterized by progressive ataxia, dementia, cataracts and tendinous xanthoma. Early diagnosis is important because it will increase the risk of dyslipidemia that can be a risk factor for coronary heart disease [3]. In this study, we report a case of cerebrotendinous xanthomatosis in our hospital and reviews the literature.

2. Case report

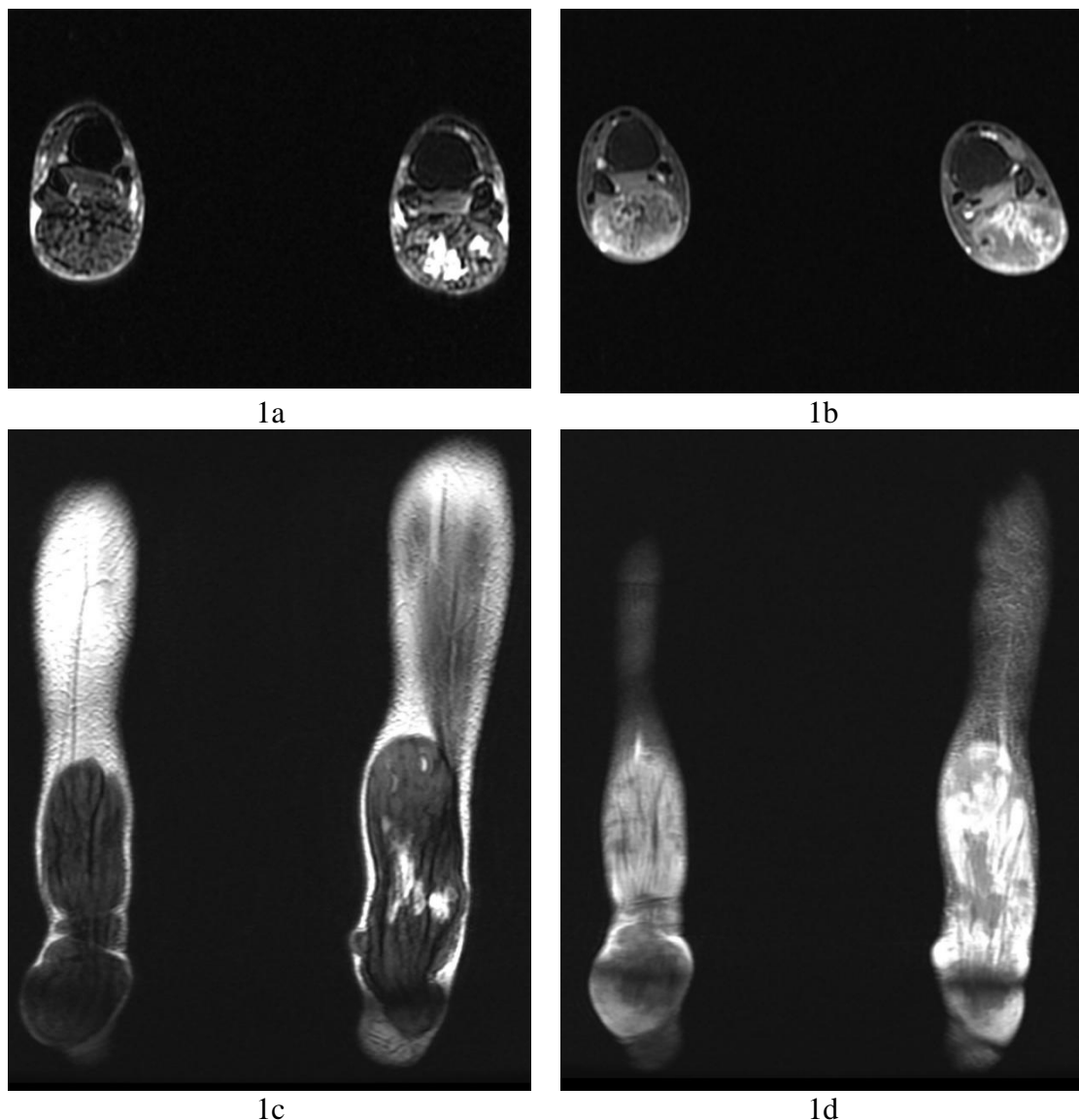


Figure 1. 57-year-old male presented with bilateral swelling of the Achilles region. (a) Axial view of the bilateral lower limb MRI on T2WI showed two lobulated masses in the bilateral Achilles region with isointensity mainly and hyperintensity centrally. (b) Axial view of the same patient using gadolinium contrast showed heterogeneous enhancement within the bilateral Achilles tendons. (c) Coronal view of the MRI from the same patient on T2WI showed fusiform swelling of both Achilles tendons. (d) Coronal view MRI of the patient with gadolinium contrast showed heterogeneous

enhancement.

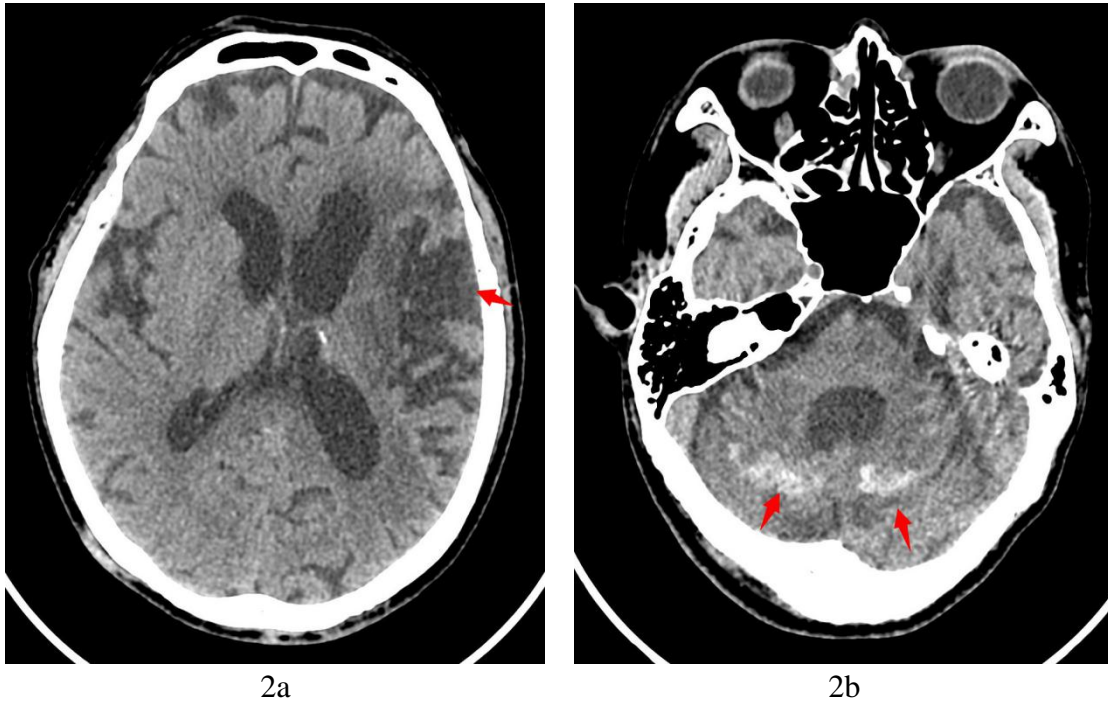


Figure 2. Axial view of non-contrast brain CT. (a) Patchy hypodense images in left temporo-frontal lobes. The ventricles, sulci and extra-axial spaces are slightly dilated. (b) Diffuse symmetrical hyperdensity in cerebellar hemispheres are again noted, and the lateral and 4th ventricles are dilated.

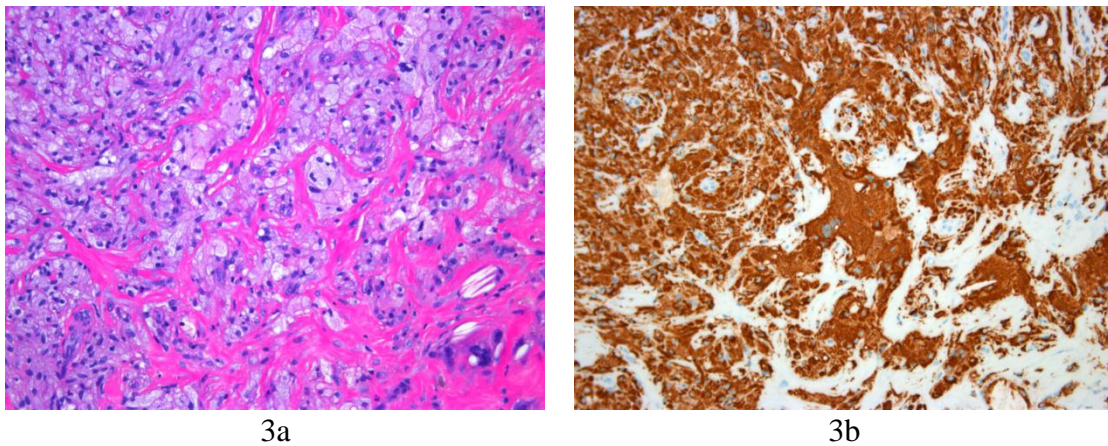


Figure 3(a) Light photomicrograph of specimen revealing the lesion is comprised of an accumulation of foam cells with fibrosis, admixed with cholesterol-containing clefts. Patches of inflammatory cells are noted, and the covering skin tissue is free from the lesion (original magnification 200; hematoxylin and eosin stain). (b) Immunohistochemistry results indicate the lesional cells are positive for CD68.

A 57-year-old male presented with a history of mental retardation, painful masses in the bilateral Achilles region and was admitted to our hospital for several months. He also presented with persistent diarrhea for many years without further assessment. He had no history of trauma. The patient had a family history of mental retardation for unknown causes and was not followed up by neurologists. After the first consultation, the patient was suspected to have chronic tophaceous gout

and the laboratory test was performed. It revealed a uric acid level of 281 $\mu\text{mol/L}$ (202-416 $\mu\text{mol/L}$). The concentration of the low density lipoproteins cholesterol(LDL) and triglyceride(TG) were 1.68 mmol/L (0.123-1.036 mmol/L) and 2.35 mmol/L (<1.7 mmol/L), respectively. Magnetic resonance imaging (MRI) showed two lobulated masses in the left and right Achilles tendon regions and the size respectively were 3.4 x 4.9 x 13.6 cm and 4.6 x 4.8 x 13.4cm, iso-intensity on T1WI and iso-hyperintensity on T2WI. Intravenous contrast revealed marked heterogeneous enhancement (Figure 1). The patient was given a biopsy and histological sections which revealed the lesion was comprised of an accumulation of foam cells with fibrosis admixed with cholesterol-containing clefts. Patches of inflammatory cells were found and the covered skin tissue was free of lesion (Figure 3a). Immunohistochemistry revealed the diseased cells were CD68 positive, while S100 and Desmin negative(Figure 3b). Brain CT showed diffuse symmetrical hyperdensity in cerebellar hemispheres and the lateral ventricle and 4th ventricle were dilated (Figure 2). The patient refused excision of the tumors and any further assessment. He also consulted a neurologist and suspected to have the CTX. In addition, genetic test (CYP27A1) was performed and the results indicated that missense mutation may occur in the CYP27A1 gene coding region. He underwent chenodexycolic acid (CDCA) replacement therapy and received a regular follow-up of the neurological outpatient and internal medicine outpatient.

3. Discussion

Cerebrotendinous xanthomatosis(CTX), also known as lipid storage disease, is an uncommon autosomal recessive genetic disease caused by the cholesterol metabolism disorder. The disorder results in the deposition of fat in nerve system, tendon and other tissues to form xanthomatosis, which is common in children and adolescents. 27-sterol- α -hydroxylase, encoded by CYP27A1 gene which is the only known pathogenic mutation associated with this disease [6], plays an important role in the conversion of cholesterol into bile acids. The lack of CYP27A1 in CTX leads to the accumulation of excessive cholesterol, triacylglycerol and phospholipids in the plasma in the dermis and tendons on the surface of the body which results in phagocytosis of macrophages [4-7]. The disease is prevalent in patients with dyslipidemia [8-9].

CTX is a lipid storage disease characterized by paroxysmal diarrhea in infants, paroxysmal cataracts in children, paroxysmal tenoxanthoma from adolescence to adulthood and paroxysmal progressive neurological dysfunction in adults (dementia, psychosis, pyramidal tract and/or small brain signs, dystonia, atypical Parkinson's disease, peripheral neuropathy and seizures).characterized by progressive ataxia, dementia, cataracts and tendinous xanthoma. The above symptoms caused by the accumulation of cholesterol in the involved tissue , leading the pathological process.

Brain MRI of CTX has some specific imaging features that showed dark gray and supratentorial white matter T2 with high intensity, micro calcification of the dentate nucleus and enlargement of the Virchow Robin space. It is well-known that the high intensity of cerebellar white matter is often symmetrical. Atrophy of the brain and cerebellum were also found in the CTX. CT examination found the hypodensity in white matter while the hyperdensity cerebellar xanthomas. Because of the failed cooperation with MRI, the patients only underwent brain CT examinations and the results revealed diffuse atrophy and bilateral focal cerebellar lesions that were consistent with the similar manifestation in MRI [16,17].

Xanthoma is one specific characteristics of CTX [10]. Xanthoma tendon is most common in extensor tendon of the Achilles tendon, elbow joint and interphalangeal joint [6]. The Achilles tendon lesions are usually bilateral and symmetrical and involve the attachment of the calcaneus but rarely cause tears in the Achilles tendon.

Ultrasound and MRI are the main imaging diagnosis methods for Achilles xanthoma. The ultrasound of xanthoma tendinous shows the anteroposterior thickness of the tendon is >7 mm and loss of normal tendon appearance with multiple hypoechoic foci in the tendon [15]. MRI of the Achilles xanthoma reveals that most of the tendons involved in the Achilles tendon are fusiform and have yellow tumors, normal thickness at the muscle, tendon junction, and calcaneal appendage. The normal structure around the tendon is well-defined, the thin layer of fat is clear and there is no abnormal change in the adjacent bone. A typical lesion on the T1WI image is a iso-hyperintense signal along the long axis of the Achilles tendon [11]. On the T2WI image, there is a lower signal shadow, which contained a speckle of short T1, long T2 and a higher signal. The T2WI fat like hyperintense region had low signals, such as combined inflammation and edema that also had a high signal. The pathological low signal area is collagen fiber, and the high signal is lipid containing foam cells and an inflammatory reaction [12]. MRI of our patient's bilateral lower limbs also showed lobulated masses in the left and right Achilles tendon region, as well as the isointensity areas on T1WI and iso-hyperintensity on T2WI.

At diagnosis, Achilles tendon xanthomas mainly need to be distinguished from tendinitis, tendon degeneration, tendon damage, gout nodule deposition, etc. They can be distinguished from morphological changes, the changes of the above lesions were light, with clear boundaries or with a history of trauma and specific laboratory examination. Besides, the bilateral and symmetrical characteristics, MRI signal and clinical blood cholesterol elevation can be used to identify the cause of Achilles tendon xanthomas. Differential diagnosis is not difficult based on the comprehensive analysis of the above indicators. Achilles tendon Xanthoma can also be caused by Familial hypercholesterolemia, but the familial hypercholesterolemia cannot involve the neurological features that can be distinguished from CTX. The main treatment methods are surgical and replacement therapy. The recurrence rate after surgical treatment is quite high if the underlying course cannot be treated initially. The medical therapy for CTX is chenodeoxycholic acid replacement. Chenodeoxycholic acid (CDCA) can normalize the synthesis of bile acid, normalize the concentration of cholesterol in plasma and CSF, and improve the neurophysiological performance [19]. HMG CoA reductase inhibitor (statin) alone or combined with CDCA can also effectively reduce cholesterol concentration and improve clinical symptoms [20].

The patient reported in this study was a male with a bilateral Achilles tendon xanthoma formation, which had gradually increased over recent years. After the age of 10, his intelligence gradually decreased and his lower limb muscle tone increased. When reviewing the patient's medical history, we found that he had relatives with the similar condition, but the cause was unknown. The patient presented with the clinical features of this rare disease such as chronic diarrhea and progressive neurological dysfunction, xanthoma tendon, mental retardation, short stature and elevated serum cholesterol levels. Brain CT showed atrophy and local lesions of the bilateral cerebellum. The patient had a similar family history, which was consistent with the clinical diagnosis of CTX. Genetic test confirmed the diagnosis. The patient in this case was recommended to use chenodeoxycholic acid (CDCA) replacement treatment. He also received HMG CoA reductase inhibitor such as statin, exercise and diet control.

After the statin and CDCA replacement therapy, the cholesterol levels of our patient returned to normal level and the clinical condition improved. The Achilles xanthoma condition remain unchanged.

4. Conclusion

In conclusion, the average diagnosis cycle of CTX is long (average 5.3 years), so clinicians should deepen their understanding about CTX. The occurrence of non-nervous system symptoms

such as double Achilles tendon swelling, and nervous system symptoms like walking instability and mental retardation, the clinicians should be highly suspect in the diagnosis of CTX. Then pathology, imaging and gene detection should be performed as soon as possible for further confirmation. This will help to reduce missed diagnoses and misdiagnoses, and achieve early diagnosis and treatment. For the brain examination, MRI is the preferred opinion, but CT can also be an opinion if the MRI is not suitable for patients.

5. Conflicts of Interest

The authors declare no conflicts of interest regarding the publication of this manuscript.

References

- [1] Federico, A., & Dotti, M. T. (2003). *Cerebrotendinous xanthomatosis: clinical manifestations, diagnostic criteria, pathogenesis, and therapy*. *Journal of child neurology*, 18(9), 633-638.
- [2] Fahey, J. J., Stark, H. H., Donovan, W. F., & Drennan, D. B. (1973). *Xanthoma of the Achilles tendon: seven cases with familial hyperbetalipoproteinemia*. *JBJS*, 55(6), 1197-1211.
- [3] Carranza-Bencano, A., Fernández-Centeno, M., Leal-Cerro, A., Duque-Jimeno, V., Gomez-Arroyo, J. A., & Zurita-Gutierrez, M. (1999). *Xanthomas of the Achilles tendon: report of a bilateral case and review of the literature*. *Foot & ankle international*, 20(5), 314-316.
- [4] Zak, A., Zeman, M., Slaby, A., & Vecka, M. (2014). *Xanthomas: clinical and pathophysiological relations*. *Biomedical Papers of the Medical Faculty of Palacky University in Olomouc*, 158(2), 181-188.
- [5] Palacio, C. H., Haring, T. R., Nguyen, N. T. T., Goss, J. A., & O'Mahony, C. A. (2011). *Homozygous familial hypercholesterolemia: case series and review of the literature*. *Case reports in transplantation*, 2011. doi:10.1155/2011/154908
- [6] Tsouli, S. G., Kiortsis, D. N., Argyropoulou, M. I., Mikhailidis, D. P., & Elisaf, M. S. (2005). *Pathogenesis, detection and treatment of Achilles tendon xanthomas*. *European journal of clinical investigation*, 35(4), 236-244.
- [7] Huri, G., & Joachim, N. (2013). *An unusual case of hand xanthomatosis*. *Case reports in orthopedics*, 2013. <https://doi.org/10.1155/2013/183018>
- [8] Gallus, G. N., Dotti, M. T., & Federico, A. (2006). *Clinical and molecular diagnosis of cerebrotendinous xanthomatosis with a review of the mutations in the CYP27A1 gene*. *Neurological Sciences*, 27(2), 143-149.
- [9] Oosterveer, D. M., Versmissen, J., Yazdanpanah, M., Hamza, T. H., & Sijbrands, E. J. (2009). *Differences in characteristics and risk of cardiovascular disease in familial hypercholesterolemia patients with and without tendon xanthomas: a systematic review and meta-analysis*. *Atherosclerosis*, 207(2), 311-317.
- [10] Nordestgaard, B. G., Chapman, M. J., Humphries, S. E., Ginsberg, H. N., Masana, L., Descamps, O. S., ... & Wiegman, A. (2013). *Familial hypercholesterolaemia is underdiagnosed and undertreated in the general population: guidance for clinicians to prevent coronary heart disease: consensus statement of the European Atherosclerosis Society*. *European heart journal*, 34(45), 3478-3490.
- [11] Farnier, M., & Bruckert, E. (2012). *Severe familial hypercholesterolaemia: current and future management*. *Archives of cardiovascular diseases*, 105(12), 656-665.
- [12] Rodriguez, C. P., Goyal, M., & Wasdahl, D. A. (2008). *Atypical imaging features of bilateral Achilles tendon xanthomatosis*. *Radiographics*, 28(7), 2064-2068.
- [13] Schweitzer, M. E., & Karasick, D. (2000). *MR imaging of disorders of the Achilles tendon*. *American Journal of Roentgenology*, 175(3), 613-625.
- [14] Nie, S., Chen, G., Cao, X., & Zhang, Y. (2014). *Cerebrotendinous xanthomatosis: a comprehensive review of pathogenesis, clinical manifestations, diagnosis, and management*. *Orphanet journal of rare diseases*, 9(1), 179.
- [15] de Ávila Fernandes, E., Santos, E. H. S., de Mello Tucunduva, T. C., Ferrari, A. J., & Fernandes, A. D. R. C. (2015). *Achilles tendon xanthoma imaging on ultrasound and magnetic resonance imaging*. *Revista Brasileira de Reumatologia (English Edition)*, 55(3), 313-316.
- [16] Schiffmann, R., & van der Knaap, M. S. (2009). *Invited article: an MRI-based approach to the diagnosis of white matter disorders*. *Neurology*, 72(8), 750-759.
- [17] Barkhof, F., Verrips, A., Wesseling, P., van der Knaap, M. S., van Engelen, B. G., Gabreëls, F. J., ... & Valk, J. (2000). *Cerebrotendinous xanthomatosis: the spectrum of imaging findings and the correlation with neuropathologic findings*. *Radiology*, 217(3), 869-876.
- [18] Moghadasian, M. H. (2004). *Cerebrotendinous xanthomatosis: clinical course, genotypes and metabolic backgrounds*. *Clinical and investigative medicine*, 27(1), 42-50.

[19] Yahalom G, Tsabari R, Molshatzki N, Ephraty L, Cohen H, Hassin-Baer S. Neurological outcome in cerebrotendinous xanthomatosis treated with chenodeoxycholic acid: early versus late diagnosis. *Clin Neuropharmacol.* 2013;36:78–83.

[20] Verrips A, Wevers RA, Van Engelen BG, Keyser A, Wolthers BG, Barkhof F, Stalenhoef A, De Graaf R, Janssen-Zijlstra F, Van Spreken A, Gabreels FJ. Effect of simvastatin in addition to chenodeoxycholic acid in patients with cerebrotendinous xanthomatosis. *Metabolism.* 1999b;48:233–8.